

Unilateral Temporomandibular Joint Dislocation after Jaw Thrust Maneuver

Case Report

Ali mohammadzadeh jouryabi¹, Ali khalighi sigaroudi², Mohammad Haghghi¹, Abbas Sedighinejad¹, Bahram Naderi nabi¹, Samaneh Ghazanfar tehran³, Nasim Ashoori sahel³

¹ Associated professor, Department of Anesthesiology, Guilan University of Medical Sciences, medical School, Rasht, Iran.

² Assistant Professor, Department of Oral And Maxillofacial Surgery, Guilan University of Medical Sciences, medical School, Rasht, Iran.

³ Resident of anesthesiology. Department of Anesthesiology, Guilan University of Medical Sciences, medical School, Rasht, Iran.

Received: 5 Jan 2015

Accepted: 15 Feb 2015

Corresponding Author:

Mohammad Haghghi

Address: Guilan, University of Medical Sciences, Rasht, Iran.

Telephone: +989113315256

Email: manesthesist@yahoo.com

Abstract

A 25-yr-old Iranian woman with incomplete abortion who was diagnosed and scheduled for dilatation and curettage procedures under general anesthesia. After premedication with Fentanyl 50µg and midazolam 2mg and enough pre-oxygenation, anesthesia was induced by sodium thiopental 250 mg and succinylcholine 60 mg with mask ventilation. After completion of procedure, the patient had a period of laryngospasm that we had to maneuvered head tilt and jaw thrust to insert an oral airway for effective ventilation. It was noted that the patient mouth was persistently open about 2 cm after removing of oral airway as the patients chin deviated to the left side. On palpation the right temporomandibular joint (TMJ) could be felt below the zygomatic arch and a diagnosis of unilateral mandibular dislocation was made. To confirm diagnosis plain radiography (anterior or posterior skull projection) was immediately taken.

TMJ dislocation was reduced by the anesthesiologist that placed his thumbs near the mandibular posterior teeth with his finger. Jaw dislocation after general anesthesia should be consider as an emergency situation that be harmful for the patients so everybody who work in the airway management must be alert to this complication. Actually, know to treat it.

Key words:

• **Temporomandibular** • **Joint dislocations**
• **General anesthesia** • **Jaw thrust.**

Case Report

A 25-yr-old Iranian woman, height 160 cm, weight 44 kg, gravid 1, parity 0, abortion 1, was admitted at 15 weeks gestation with abnormal vaginal bleeding for a week. Incomplete abortion was diagnosed and the patient was scheduled for dilatation and curettage procedure under general anesthesia. In preoperative evaluation that was taken by her, she revealed an ASA physical status II, malampathy scoring was grade II. In addition, a history of mild anemia, but she was healthy otherwise. The patient had a previous appendectomy under general anesthesia, 14 months previously, without surgical or anesthetic complications. Her ability to open her mouth and flex/extend the neck was normal. She had a good dental healthy without any abnormality or history of surgery on oral cavity. After pre-oxygenation, anesthesia was induced with sodium thiopental 250 mg; fentanyl 50 μ g and midazolam 2 mg.

After establishing an adequate airway, succinylcholine 60 mg was administered.

The chin lift technique was performed to control the patient's ventilation with halothane through a facemask for 5 minutes. There were no problems during mask ventilation anesthesia. After completion of procedures, the patient had a period of laryngospasm that we had to maneuvered head tilt and jaw thrust to insert an oral airway for effective ventilation.

It was noted the patient mouth was persistently open about 2 cm after remove of oral airway as the patient's chin deviated to left. In the recovery room she was fully awaked and complained of jaw pain, and her mouth was remained slightly opened (approximately 2 cm). She had pain in the right temporomandibular joint (TMJ) and lost the ability to open and close her mouth (figure-1, 2). On palpation the right tm joint (TMJ) could be felt below the zygomatic arch and a diagnosis of mandibular dislocation was made. A radiography of skull –AP x ray was taken to examine TMJ dislocation, immediately (figure-3, 4). In addition, anterior dislocation of right mandibular condyle diagnosis was confirmed. In addition it should be noted that the degree of TMJ deviation in radiography was not measured. Since dislocation could not be readily reduced, in the manipulation of mandible it was necessary that

patient was sedated by 3mg IV midazolam. Anesthesiologist was placed his thumbs near the posterior teeth with his finger grasping lower edge of mandible. downward pressure on the posterior teeth (slightly more than in right side) and upward movement of the chin. Along with posterior displacement of the entire mandible, dislocation was readily reduced. The pain relief was quickly and she regains full jaw movement.

Discussion

Temporomandibular joint (TMJ) instability, while not always symptomatic, has a prevalence of up to 25–50% in the general population, and is most common in middle aged females.^(1,2) Such instability may have important implications for airway management during anesthesia. Temporomandibular joint dislocation occurs when the condyle is displaced anterior to the auricular eminence and the patient unable to reduce itself back into the glenoid fossa.⁽³⁻⁶⁾

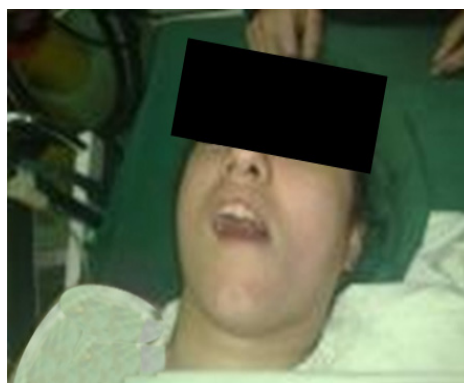

Figure 1. TMJ dislocation

A lot of factors causing TMJ dislocation. hyperextension, yawning, wide mouth opening during mastication, vomiting, trauma, seizure, flexion – extension of mandible, dental procedure, Use of the laryngeal mask airway anesthesia or diagnostic procedures, direct laryngoscopy for intubation, Parkinson disease, drug such as phenothiazine can cause extra pyramidal movement that affect the mandible.⁽⁶⁻⁹⁾ Dislocation of TM joint can occur either in awake patient that experience forced voluntary opening of mouth during yawning, boroncoscopy even in patient under general anesthesia, several studies have reported that yawning after induction by Thiopental or Propofol can lead to dislocation of TM joint, particularly in association with muscle relaxation.^(9, 10)

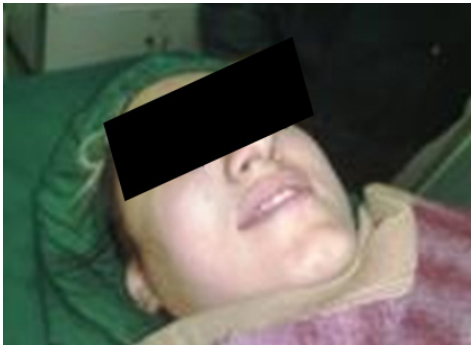

Figure2. After TMJ dislocation reduction

TMJ dislocation may be happened unilaterally or bilaterally. A dislocated condyle will usually created a concave facial appearance just anterior to the tragus.⁽⁷⁻⁹⁾ In unilateral dislocation the chin deviate to contralateral side of the dislocation. Bilateral dislocation cause anterior open bite in case of mandibular fractures and TMJ dislocation patient have periauricular edema and tenderness.^(5, 6, 8) Rather than the typical concave appearance of a patient with a dislocation, panoramic radiographic examination is used to confirm the diagnosis.⁽¹¹⁾ The degree of displacement or damage of articular soft tissue can be determined by MRI.⁽¹²⁻¹⁴⁾

Once TMJ dislocation is occurred, the treatment must be done as soon as possible by local anesthetic blocks of the TM joint, auriculotemporal nerve, and lateral petrygoid muscle that provide the patient comfort during reduction.

For reduction of TM joint dislocation the surgeon or anesthesiologist must standing in front of the patient and it is better the patient head supported by chair or table. The surgeons thumbs, which are placed over the occlusal surfaces of the mandibular molar teeth or the posterior portion of residual alveolar ridge in edentulous patient, and the remaining fingers are place under inferior border of mandible, the patient instructed to relax the jaw and then downward and backward movement. (figure-5). If reduction is unsuccessful after two attempt, muscle relaxation and sedation(rarely general anesthesia) must be performed. After reduction of dislocated condyle, limitation of jaw movement must be prescribed for several days and external dressing over the chin and head may be useful.^(5, 6) If dislocation is not obvious, then consider other conditions, such as fracture, hemarthritis, closed lock of the joint

meniscus, and myofascial pain. After reducing the dislocation it will be comforting to apply a soft cervical collar to reduce the range of motion at the temporomandibular joint (TMJ). Recommend a soft diet and instruct the patient to refrain from opening his mouth too widely. Prescribe analgesics if needed.⁽¹⁵⁾

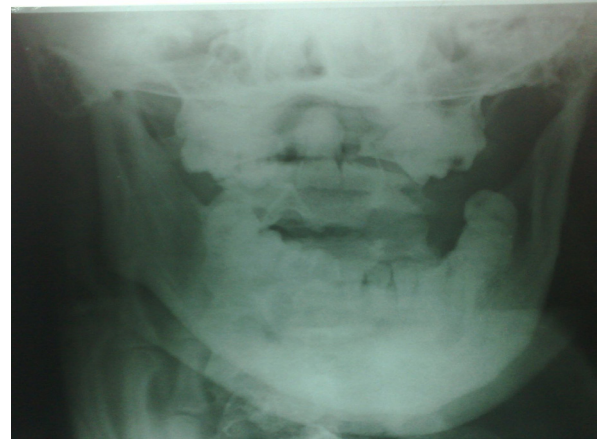


Figure3. Anteroposterior x-ray view

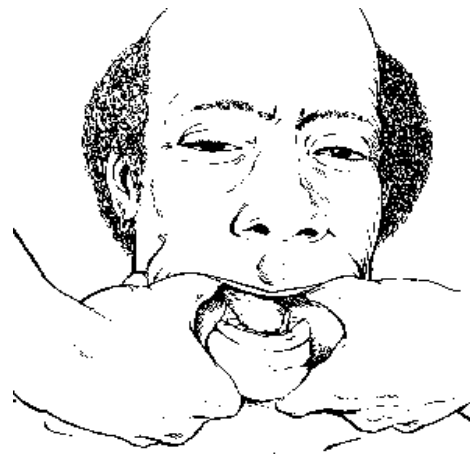

Figure4. technique of reduction of jaw dislocation

Conclusion

Jaw dislocation is not a common clinical syndrome after general anesthesia, but every changes in the face morphology should be rouled out as mandibular dislocation. Especially, in the mandiblur patient zone.

References

1. LeResche L. Epidemiology of temporomandibular disorders: implications for the investigation of etiologic factors. *Crit Rev Oral Biol Med*. 1997;8(3):291-305. PubMed PMID: 9260045. eng.
2. Aiello G, Metcalf I. Anaesthetic implications of temporomandibular joint disease. *Canadian journal of anaesthesia = Journal canadien d'anesthésie*. 1992 Jul;39(6):610-6. PubMed PMID: 1643688. eng.
3. Sosis M, Lazar S. Jaw dislocation during general anaesthesia. *Canadian journal of anaesthesia = Journal canadien d'anesthésie*. 1987 Jul;34(4):407-8. PubMed PMID: 3608062. eng.
4. Luyk NH, Larsen PE. The diagnosis and treatment of the dislocated mandible. *The American journal of emergency medicine*. 1989 May;7(3):329-35. PubMed PMID: 2653332. eng.
5. Shun TA, Wai WT, Chiu LC. A case series of closed reduction for acute temporomandibular joint dislocation by a new approach. *Eur J Emerg Med*. 2006 Apr;13(2):72-5. PubMed PMID: 16525232. eng.
6. Agro F, Salvinelli F, Casale M, Antonelli S. Temporomandibular joint assessment in anaesthetic practice. *British journal of anaesthesia*. 2003 May;90(5):707-8. PubMed PMID: 12697609. eng.
7. Small RH, Ganzberg SI, Schuster AW. Unsuspected temporomandibular joint pathology leading to a difficult endotracheal intubation. *Anesthesia and analgesia*. 2004 Aug;99(2):383-5, table of contents. PubMed PMID: 15271711. eng.
8. Rastogi NK, Vakharia N, Hung OR. Perioperative anterior dislocation of the temporomandibular joint. *Anesthesia and analgesia*. 1997 Apr;84(4):924-6. PubMed PMID: 9085984. eng.
9. Gambling DR, Ross PL. Temporomandibular joint subluxation on induction of anesthesia. *Anesthesia and analgesia*. 1988 Jan;67(1):91-2. PubMed PMID: 3337354. eng.
10. Avidan A. Dislocation of the temporomandibular joint due to forceful yawning during induction with propofol. *Journal of clinical anesthesia*. 2002 Mar;14(2):159-60. PubMed PMID: 11943534. eng.
11. Epstein JB, Caldwell J, Black G. The utility of panoramic imaging of the temporomandibular joint in patients with temporomandibular disorders. *Oral surgery, oral medicine, oral pathology, oral radiology, and endodontics*. 2001 Aug;92(2):236-9. PubMed PMID: 11505273. eng.
12. Umstadt HE, Lalyko G, Hochban W, Austermann KH. [Function and morphology of the temporomandibular joint after mandibular translocation osteotomies with and without positioning plates]. *Mund Kiefer Gesichtschir*. 1998 May;2 Suppl 1:S177-82. PubMed PMID: 9658849. Kiefergelenkfunktion und -morphologie nach Unterkieferumstellungsosteotomien mit und ohne Positionierungsplatten. ger.
13. Summa S, Ursini R, Manicone PF, Molinari F, Deli R. MRI assessment of temporomandibular disorders: an approach to diagnostic and therapeutic setting. *Cranio : the journal of craniomandibular practice*. 2014 Apr;32(2):131-8. PubMed PMID: 24839724.
14. Larheim TA. Role of magnetic resonance imaging in the clinical diagnosis of the temporomandibular joint. *Cells, tissues, organs*. 2005;180(1):6-21. PubMed PMID: 16088129.
15. Robert D. marciani, Eric R. carlson, Thomas W. Braun, "oral and maxillofacial surgery" VOL 2 pages 905, 906, 2009 saunders Elsevier. ISBN 1-4160-6655-2