

Surgical Management of pleural Complications of Lung and Liver Hydatid Cysts in 34 Patients

Manoucher Aghajanzadeh, Mohammad Reza Asgary, Ali Alavi Foumani, Syrus Emir Alavi, Siamak Rimaz, Zohre Banihashemi, Ehsan Hajipoor and Sara Massahnia

International Journal of Life Sciences

ISSN No. 2091-0525



DOI-
dx.doi.org/10.3126/ijls.v8i4.10893



Research Article

Surgical Management of pleural Complications of Lung and Liver Hydatid Cysts in 34 Patients

Manoucher Aghajanzadeh¹, Mohammad Reza Asgary¹, Ali Alavi Foumani¹, Syrus Emir Alavi¹, Siamak Rimaz¹, Zohre Banihashemi¹, Ehsan Hajipoor¹ and Sara Massahnia¹¹ Pulmonary Diseases & TB Research Center of Guilan University Medical Sciences, Razi Hospital, Rasht, Iran

Article Information

Submitted: June, 2014

Revised: June, 2014

Accepted: June, 2014

Key words:

Pulmonary and liver
hydatidosis;

Pleural complications;

Surgery

ABSTRACT

The aim of this retrospective study was to review pleural complications and results of surgical management of patient with hydatid disease. Between 2000 and 2010, 34 patients among 260 patients with hydatid disease, were diagnosed with pleural complications. Findings are presented in relative frequencies tables. The most common pleural complication was empyema in 9 patients. The most common procedure was cystotomy, evacuation and decortication in 25 patients. In endemic area, pleural complications of hydatid cyst should be considered for differential diagnosis. And because of higher morbidity and mortality, surgical treatment should be carried out before complications.

INTRODUCTION

Hydatid disease still remains an important health problem in Iran (Aghajanzadeh, et al., 2008). Although it can be found in any part throughout the body, it is more common in the liver (75%) and lung (25%) (Aghajanzadeh, et al., 2008; Aribas, et al, 2002). Concomitant pulmonary and liver hydatid cysts occur in 4% to 25% of patients with echinococcosis (Aghajanzadeh, et al., 2008). It is needed to investigate the possibility of new cysts in patients diagnosed with either a pulmonary or hepatic cyst (Aghajanzadeh, et al., 2008). Intrapleural rupture occurs in 5% of cases and may produce an acute clinical picture as intense chest pain, persistent cough, severe dyspnea, cyanosis, shock, and suffocation (Aghajanzadeh, et al., 2008; Aribas, et al, 2002). Liver cysts can also rupture into the peritoneum causing peritonitis, or trans diaphragmatically into the pleural space or bronchial tree causing pulmonary hydatidosis or a bronchial fistula (Aghajanzadeh, et al., 2008). The most frequent complication of pulmonary hydatid disease is the rupture of the cyst into tracheo-bronchial tree (Aribas et al., 2002; Doğan et al., 1989). If a cyst

rupture into the pleura or pulmonary parenchyma, it can be a severe and life-threatening problem (Kilani et al., 2001; Oğuzkaya et al, 1997). We evaluated 34 patients with pulmonary and liver hydatid disease with pleural complications and show our experiences by discussing the presentation, diagnostic and therapeutic procedures and outcome of patients.

MATERIALS AND METHODS

The records of 260 patients with hydatid disease of lung and liver admitted in the Department of Thoracic Surgery in Razi and Arya Hospital of Guilan University of Medical sciences in Gilan, which is one of the endemic area for hydatid disease (Aghajanzadeh, et al., 2009), from 2000 to 2010 were reviewed retrospectively. We evaluated patients according to age, sex, complications, symptoms, radiologic and laboratory findings, types of surgical interventions, length of postoperative period, and postoperative morbidity and mortality and outcome of patients. The first diagnosis was based on chest radiography, ultrasonography (thorax and abdomen), and computed tomography of the chest. Serological

* Correspondence to: Mohammad Reza Asgary, Pulmonary Diseases & TB Research Center of Guilan University Medical Sciences, Razi Hospital, Rasht, Iran

Email: tsagary85@yahoo.com; Phone no - 098 - 912247714

Cite this article as -

Aghajanzadeh, M.; Asgary, M.R.; Foumani, A. A.; Alavi, S. E.; Rimaz, S.; Banihashemi, Z.; Hajipoor, E.; Massahnia, S. (2014) Surgical Management of pleural Complications of Lung and Liver Hydatid Cysts in 34 Patients. *International Journal of Life Sciences* 8(4): 15 - 19.

Doi: dx.doi.org/10.3126/ijls.v8i4.10893

hydatid tests (anti-Echinococcus antibodies, indirect hemagglutination, immunoelectrophoresis and ELISA) were used. All patients were treated surgically. The mean follow-up period was 24 months.

RESULTS

Among 260 patients with lung, liver and rib hydatid cysts, 34 patients (Aytaç net al., 1977; 73%) had pleural and pulmonary parenchymal complications - 22 male and 12 female- ranging from 4 to 64 years (mean age was 26 year). Pleural complications were investigated in 30 patients (88.24%) and pulmonary complications were seen in 4 patients (11.76%). The most Pleural complication was empyema in 9 patients (26%) (loculated empyema in 5 patients) (Figure Aghajanzadeh et al., 2008), secondary spontaneous pneumothorax in 6(17%), hydropneumothorax in 6(17%) (Figure 3), tension pneumothorax in 3(8%), pleural effusion in 4 (11%), hepatopleural fistula in 4(11%) (Figure 4) and hepatobronchial fistula in 3 patients (8%) (Table1). The most common symptoms were chest pain in 24(79.1%), dyspnea in 20 (58.82%) and cough in 16 patients (47%) (Table 2). In all 34 patients, one or more symptoms (chest pain, dyspnea etc) were present. The most common finding in radiologic investigations were air-fluid level in 10 patients (Figure 5,6) and other findings have been shown in Table 3.

Table 1. Frequency of pleural complications in 34 patients with pulmonary, liver and rib hydatid cysts

Pleural complications	Number of patients (%)
Empyema	9 (26.47)
Secondary spontaneous pneumothorax	6 (17.64)
Hydropneumothorax	6 (17.64)
Tension pneumothorax	3 (8.82)
Pleural effusion	3 (8.82)
Hepatopleural fistula	4 (11.76)
Hepatobronchial fistula	3 (8.82)

Table 2. Frequency of patient's symptoms in 34 of patients with pleural complications of pulmonary, liver and rib hydatid cysts

Symptoms	Number of patients (%)
Chest pain	24 (70.58)
Dyspnea	20 (58.82)
Cough	16 (47)
Sputum production	12 (35)
Fever	14 (41)
Hemoptysis	6 (17.64)
Abdominal pain	4 (11.76)
Vesicle expectoration	2 (2.88)
Fatigue	8 (23.52)
Biloptysis	2 (2.88)

We also found pneumonic infiltration in 2 patients .Sero-logical hydatid tests (anti-Echinococcus antibodies, indirect hemagglutination, immunoelectrophoresis and ELISA) were positive only in 18 patients. With ultrasonographic and CT-scan examination of abdomen, 12 hydatid cysts were established in the liver which most of them were on the dome the liver. All patients were treated surgically (Table 4). The most common procedure was cystotomy, evacuation and decortication in 25 patients. First procedure in 23 patients was closed-tube drainage, and they were operated after stabilizing their general status, Posterolateral thoracotomy in 22 patients, Antero-lateral thoracotomy in 12 patients and Posterolateral and Antero-lateral thoracotomy with pherotomy in 8 patients with liver-dome cysts. In 4 patients with bilateral disease, one stage of Antero-lateral thoracotomy was performed. When the cyst was on the periphery of lung, wedge resection was performed or when lung was destroyed or underwent bronchiectasis, segmentectomy or lobectomy was performed. In 30 of the cases, decortication was added to the procedures. Albendazole was used at least 3 month postoperatively (10 mg / kg/ daily). The mean postoperative hospital stay was 14 days \ (6-25 days). A 60-year-old woman with a liver hydatid cyst and hepatobronchial fistula died because of organ failure, developing after lobectomy and decortication and also onset of staphylococcus sepsis. Postoperative complications were as follow: Three patients had pneumonia, two had atelectasis, one had wound infection and in one patient, persistent air leakage was present and lung was not completely reexpand. This patient managed with chest physiotherapy, broncoscopy and tube thoracostomy. Mean follow- up period was 24 months (ranges from 8 to 40 months). No recurrence was observed in our patients.

Table 3. The Frequency of patients radiologic findings in 34 patients with pleural complications of pulmonary, liver and rib hydatid cysts

Radiologic findings	Number of patients (%)
Air-fluid level	10(29.41)
Multiloculated empyema	5 (14.70)
Homogeneous density	5 (14.70)
Pulmonary collapse	5 (14.70)
Pleural effusion	5 (14.70)
Water-lily sign	2 (5.88)
Pulmonary infiltration with effusion	2 (5.88)

DISCUSSION

Hydatid cyst still remains an important problem in developing countries(Aghajanzadeh et al., 2008). It can appear in any place throughout the body and is more common in the liver (75%) and lung (20%)(Aghajanzadeh et al., 2008; Doğan et al., 1989). The first station of the larvae taken orally through the portal system is the liver. Therefore it is more common in the liver (75%),

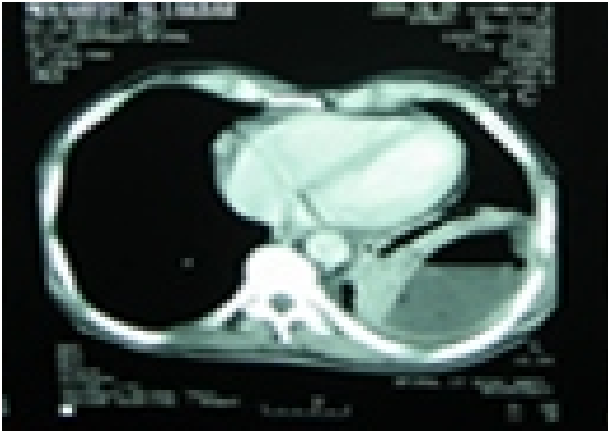


Figure 1. CT-scan, show pleural empyema caused by rupture of pulmonary hydatid cyst in pleural space

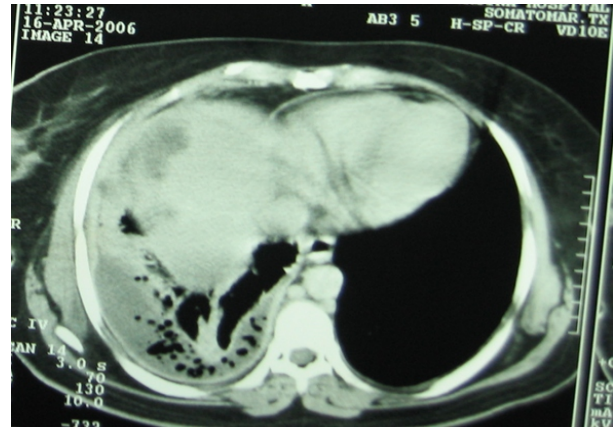


Figure 2. CT-scan, show pleural effusion caused by rupture of liver hydatid cyst in pleural space and daughter cysts

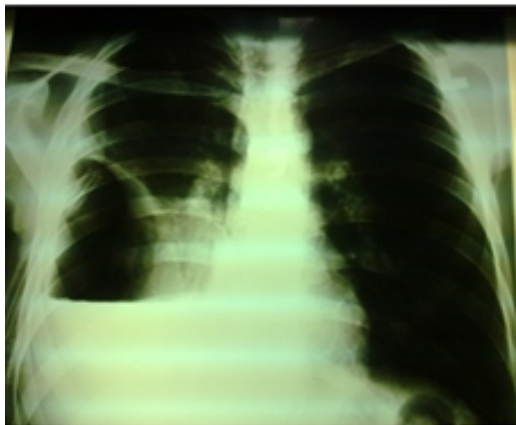


Figure 3. CXR, show hydropneumothorax caused by rupture of pulmonary hydatid cyst in pleural space

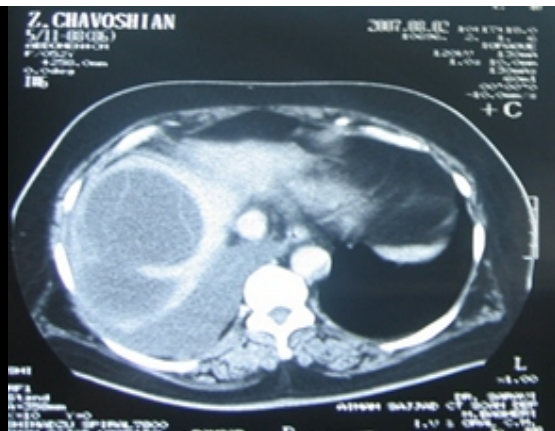
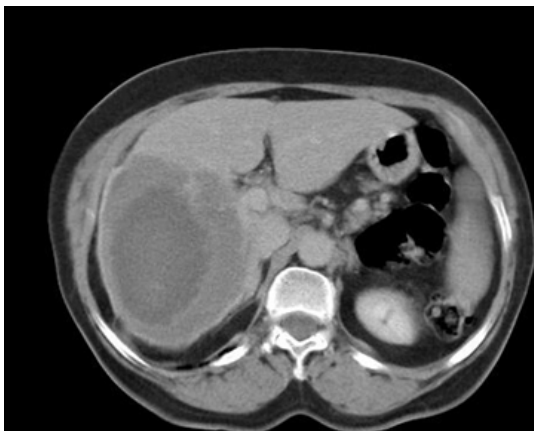

Figure 4 CT-scan of the chest show intrapleural ruptured of liver hydatid cyst

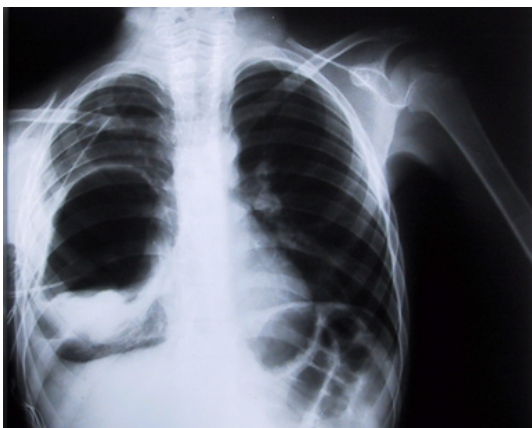

Figure 5. CXR, show hydropneumothorax caused by rupture of pulmonary hydatid cyst in pleural space and water lily sign

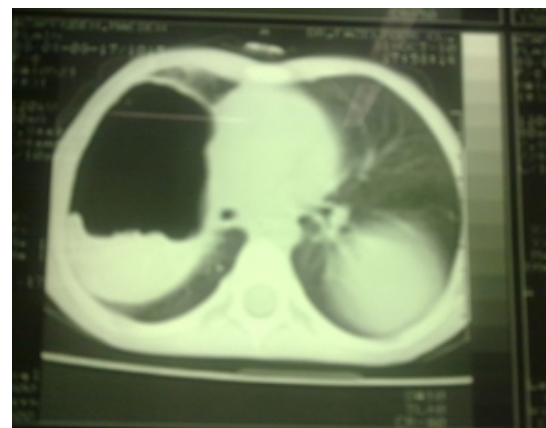

Figure 6. CT-scan, show hydropneumothorax and water lily sign caused by rupture of pulmonary hydatid cyst in pleural space

followed by the lungs. Although the larvae can enter the lungs through the lymphatic system or the bronchial system, it is thought that cysts settled down in the lungs are usually larvae that could have passed through the sinusoids (Doğan et al., 1989; Aytac net al., 1977; Burgos et al., 1999). Thus 90% of the patients with hydatid disease are from rural areas (Doğan et al., 1989).

Table 3. The Frequency of patients radiologic findings in 34 patients with pleural complications of pulmonary, liver and rib hydatid cysts

Complication	Surgical techniques	Number of patients (%)
Pleural	Cystotomy + capitonnage	4 (11.76)
	Cystotomy + capitonnage + decortication	12 (35.2)
	Cystectomy + decortication	4 (11.76)
	Segmentectomy+decortication	2 (5.88)
	Lobectomy+ decortication	3 (8.82)
	Radical pulmonary resection	1(2.94)
Liver	Thoracophrenotomy	3 (8.82)
	Cystotomy+ drainage	
	Thoracophrenotomy	4 (11.76)
	Cystotomy+ decortications	
Rib	Thoracotomy+rib resection+decoetication	1(2.94)

Hydatid disease frequently involves only one organ, but cysts presented both in lungs and liver comprise 10% of all cysts (Doğan et al., 1989). Hydatid disease is seen in any age and sex group, although it is more common in patients with 20 to 40 years of age (Doğan et al., 1989, Zapatero et al., 1988). In our study, the male/female ratio was 2/1, and the mean age of the patients was 26 years. Although the Casoni skin test, the Weinberg fixation test, eosinophilia, and sedimentation rate are reported to be significant in ruptured cysts (Burgos et al., 1999), they have not been routinely used because of low diagnostic efficiencies (Doğan et al., 1989). We did not use these tests routinely, except in a few cases. The first valuable diagnostic method in pulmonary hydatid disease is the plain chest radiogram (Aghajanzadeh et al., 2008; Doğan et al., 1989; Aribas et al., et al., 2000). In our study the first image for pulmonary hydatid cyst is plain chest radiography. In intact cysts, typical images appear as round or oval, sharp-edged or homogeneous densities, but in complicated cysts, images appear as meniscus sign, water-lily sign, cavity with or without air-fluid levels, and collapse of the lung (Doğan et al., 1989). Computed tomography of the chest clearly defined the cysts situation and complications of cysts (Doğan et al., 1989; Aribas et al., 2000). In our cases -as other studies- we also found computed tomography of the chest have significant value in complicated hydatid cysts, pleural thickening, empyema and infiltrating parenchyma (Doğan et al., 1989; Aytac net al., 1977; Solak et al., 1988). Ultrasonography is important diagnostic methods, particularly in the assessment of hepatic cysts (Oğuzkaya et al., 1997). Rupture of the cyst into the pleural or pericardial cavities is serious (Kilani et al., 2005, Hadley, 1985). The raising morbidity of these complications is the result of the rupture of cysts in lungs or in the dome of the liver (Burgos et al., 1999; Hadley, 1985). Although pleural complications are reported to be 0.5% to 18.2% (Aribas et al., et al., 2000; Kilani et al., 2005; Mutaf et al., 1994) in the literature, it is considered that the pleural necrosis after the pressure of pulmonary cysts, especially those found peripherally and subpleurally, has an important role in the rupture of

cysts into the pleural cavity (Athaniassiadi et al., 1998). In the cysts at the dome of the liver, it is accepted that the pressure and the irrigative effect of bile are responsible for the rupture of diaphragm (Kilani et al., 2005). Six patients were admitted with secondary spontaneous pneumothorax and 9 patients with empyema. The primary treatment of pulmonary hydatid disease is surgical intervention (Mutaf et al., 1994; Athaniassiadi et al., 1998) although chemotherapy is used as a complement to surgical treatment to avoid recurrences or is applied in non-surgical cases because of lack of enough cardiac or pulmonary performance status (Doğan et al., 1989). The aim in surgical intervention is mainly the removal of the germinative membrane without causing intraoperative contamination and prevention of an intrapulmonary residual cystic space. For this purpose, varying techniques, such as enucleation, pericystectomy, and simple cystotomy with or without capitonnage of the pericystic space, can be chosen in proper conditions during the operation (Zapatero et al., 1988; Solak et al., 1988; Halezeroglu et al., 1997). Cystotomy or cystectomy and capitonnage are commonly applied in surgical procedures (Doğan et al., 1989; Halezeroglu et al., 1997; Qian, 1988). In our patients, we usually carried out cystotomy with or without capitonnage and cystectomy. When the cystic cavity was being obliterated, large bronchial openings were closed first, and then the cavity was obliterated by purse-string sutures from in base to top of cavity. But, besides those procedures, decortication rate in our experience was higher because of the pleural thickening and complications of the patients was higher than others (25 patients) (Aribas et al., 2002; Kilani et al., 2005; Athaniassiadi et al., 1998). Radical pulmonary resections should be performed when the pulmonary parenchyma around the cyst is destroyed and lung could not be expanded (Aytac net al., 1977, Gashi et al., 1988). We performed this procedure in one of our patients.

Recently, the most popular intervention in several bilateral pulmonary cysts with or without hepatic cysts is sternotomy or anterior bilateral thoracotomy and we consider it suitable for removal of all cysts in one stage (Dhaliwal et al., 1997). Instead, staged thoracotomy is a safer and more reliable procedure (Zapatero et al., 1988). We also performed two stage thoracotomy in 4 patients with bilateral cysts, the complicated side first and the contralateral side after 2 months. It is more proper to carry out thoracophrenotomy for when hydatid cysts involved right lung and the liver or if a hepatic cyst causes only a pleural complication without a pulmonary cyst, the suitable procedure is thoracophrenotomy (Kilani et al., 2005), which was applied in 4 patients of our series. In synchronous pulmonary and hepatic cysts, postoperative morbidity was to be 3.5% (Doğan et al., 1989). The rate of complication in our series happened in seven patients. This findings may show that the complication in hydatid cysts with pleural complications is higher than in intact cases (Aribas et al., 2002).

DISCUSSION

In endemic areas of hydatid cysts, pulmonary complications of echinococcosis diseases as spontaneous pneumothorax, empyema, hepatobronchial fistula and pleural effusion should be considered for differential diagnosis. Since hydatid cysts with pleural complications are associated with higher morbidity and mortality, surgical

treatment should be carried out for hydatid cyst before such complications was occurs

REFERENCES

- Aghajanzadeh M, Safarpour F, Amani H, Alavi A. One-stage procedure for lung and liver hydatid cysts. *Asian Cardiovascular and Thoracic Annals*. 2008;16(5):392-5.
- Aghajanzadeh M, Molaie R, Aghajanzadeh H, Marandi KF. Hydatid Cyst as a Cause of Pancoast's Syndrome. *Arch Iran Med*. 1999;2(1).
- Aribas OK, Kanat F, Gormus N, Turk E. Pleural complications of hydatid disease. *The Journal of thoracic and cardiovascular surgery*. 2002;123(3):492-7.
- Doğan R, Yüksel M, Cetin G, Süzer K, Alp M, Kaya S, et al. Surgical treatment of hydatid cysts of the lung: report on 1055 patients. *Thorax*. 1989;44(3):192-9.
- Kilani T, El Hammami S, Horchani H, Ben Miled-Mrad K, Hantous S, Mestiri Ia, et al. Hydatid disease of the liver with thoracic involvement. *World journal of surgery*. 2001;25(1):40-5.
- Oğuzkaya F, Akçali Y, Kahraman C, Emiroğullari N, Bilgin M, Şahin A. Unusually located hydatid cysts: intrathoracic but extrapulmonary. *The Annals of Thoracic Surgery*. 1997;64(2):334-7.
- Aghajanzadeh M, Sadeghi S, Joafshani MA, Jafari M, Esmaili Delshad MS. Clinical sign, symptoms, diagnosis and outcomes of patients with complicated lung hydatid cyst. *Journal of Gilan University of Medical Sciences*. 2009;18:1-2.
- Aytaç A, Yurdakul Y, İkizler C, Olga R, Saylam A. Pulmonary hydatid disease: report of 100 patients. *The Annals of Thoracic Surgery*. 1977;23(2):145-51.
- Burgos R, Varela A, Castedo E, Roda J, Montero CG, Serrano S, et al. Pulmonary hydatidosis: surgical treatment and follow-up of 240 cases. *European journal of cardio-thoracic surgery*. 1999;16(6):628-35.
- Zapatero J, Madrigal L, Lago J, Baschwitz B, Perez E, Candelas J. Surgical treatment of thoracic hydatidosis. A review of 100 cases. *European journal of cardio-thoracic surgery: official journal of the European Association for Cardio-thoracic Surgery*. 1988;3(5):436-40.
- Topçu S, Kurul IC, Taştepe I, Bozkurt D, Gülhan E, Çetin G. Surgical treatment of pulmonary hydatid cysts in children. *The Journal of thoracic and cardiovascular surgery*. 2000;120(6):1097-101.
- Solak H, Özgen G, Yüksek T, Eren N, Solak N, Kirca NK, et al. Surgery in hydatid cyst of the lung: A report of 460 cases. *Scandinavian Cardiovascular Journal*. 1988;22(2):101-4.
- Hadley M. Occult hydatid disease presenting as a spontaneous pneumothorax. *British journal of radiology*. 1985;58(692):770-2.
- Mutaf O, Arikan A, Yazici M, Erdener A, Özok G. Pulmonary Hydatidosis in Children. *European journal of pediatric surgery*. 1994;4(02):70-3.
- Athanassiadi K, Kalavrouziotis G, Loutsidis A, Bellenis I, Exarchos N. Surgical treatment of echinococcosis by a transthoracic approach: a review of 85 cases. *European journal of cardio-thoracic surgery*. 1998;14(2):134-40.
- Halezeroglu S, Celik M, Uysal A, Senol C, Keles M, Arman B. Giant hydatid cysts of the lung. *The Journal of thoracic and cardiovascular surgery*. 1997;113(4):712-7.
- Qian Z. Thoracic hydatid cysts: a report of 842 cases treated over a thirty-year period. *The Annals of Thoracic Surgery*. 1988;46(3):342-6.
- Gashi M, Beqiri S, Guguli M, Recica X, Ahmedi E. Our experiences in surgical treatment of thoracic echinococcosis during the period 1977-1986. *space*. 1988;48:32.7.
- Dhaliwal RS, Kalkat MS. One-stage surgical procedure for bilateral lung and liver hydatid cysts. *The Annals of Thoracic Surgery*. 1997;64(2):338-41.

© International Journal of Life Sciences

NOTE: Authors/contributors are responsible for originality, contents, correct references, and ethical issues.

Submit your next manuscript to IJLS with a -

- 1. Convenient online submission,**
- 2. Rapid editorial review followed by peer review,**
- 3. Immediate publication on acceptance.**